

Successful Treatment of Stereotactic Body Radiation Therapy Combined with Transarterial Chemolipiodolization for Hepatocellular Carcinoma with Biliary Obstruction

Chan-Kwon Park¹, Si-Hyun Bae^{1,3}, Hong-Jun Yang¹, Ho-Jong Chun², Il-Bong Choi², Jong-Young Choi^{1,3}, and Seung-Kew Yoon^{1,3}

Departments of ¹Internal Medicine and ²Radiation Oncology, The Catholic University of Korea School of Medicine; ³WHO Collaborating Center for Reference and Research on Viral Hepatitis, Seoul, Korea

Conventional radiation therapy (RT) is a widely recognized treatment for hepatocellular carcinoma (HCC). However, conventional RT plays only a limited role in HCC treatment because of its low efficacy and the low tolerance of the liver for this modality. Stereotactic body radiation therapy (SBRT) was recently developed and represents the most advanced radiation therapy technique currently available. It can deliver a high dose in a short time to well-defined hepatic tumors, with rapid dose fall-off gradients. We believe that SBRT with transarterial chemolipiodolization (TACL) may prove promising as a combined treatment modality for HCC due to its precision and relative safety. Here we present a case of successful treatment of advanced HCC with obstructive jaundice using this combined modality. (**Korean J Intern Med** 2011;26:94-98)

Keywords: Hepatocellular carcinoma; Stereotactic body radiation therapy; Transarterial chemolipiodolization; Obstructive jaundice

INTRODUCTION

Conventional radiation therapy (RT) is a widely recognized treatment for hepatocellular carcinoma (HCC). However, conventional RT currently plays only a limited role in HCC treatment due to its low efficacy and the low tolerance of the liver for its effects. The total dose of irradiation has been shown to be the most significant factor associated with response [1]. Cell survival with lengthy treatment time was increased, presumably as a consequence of cellular repair mechanisms. To improve local tumor control and overall survival, dose escalation during short treatments has become an important issue. It is not possible with conventional RT to deliver a high radiation dose to a treatment volume in a short time without also

irradiating some normal hepatic tissue with a high dose. Stereotactic body radiation therapy (SBRT) is the only modality that can deliver a high dose in a short time to well-defined hepatic tumors with a rapid dose fall-off gradient. SBRT was initially used only for benign and malignant intracranial lesions with the advent of advanced imaging techniques and robotic image-guided radiation technologies [2,3].

Recently, local, not whole liver, RT has been attempted by several investigators, and this work has demonstrated that high doses of radiation can be safely delivered to a portion of the liver [4]. These results suggest a benefit of the combination of radiation and chemotherapy for advanced HCC with portal vein tumor thrombosis (PVTT).

Here we report the use of CyberKnife with transarterial

Received: July 31, 2007

Revised : September 3, 2007

Accepted: June 10, 2008

Correspondence to Si-Hyun Bae, M.D.

Department of Internal Medicine, Seoul St. Mary's Hospital, The Catholic University of Korea, 505 Banpo-dong, Seocho-gu, Seoul 137-040, Korea

Tel: 82-2-2258-6020, Fax: 82-2-3481-4025, E-mail: baesh@catholic.ac.kr

chemolipiodolization (TACL) treatment for advanced HCC developing extrahepatic biliary obstruction (EHBO), which showed a partial response and safety.

CASE REPORT

A 63-year-old man was admitted to our hospital complaining of epigastric discomfort and jaundice. He was diagnosed as a hepatitis B virus (HBV) carrier, a status he had held for 20 years without receiving treatment. He had complained of epigastric discomfort with abdominal bloating and jaundice with pruritus a few months previously associated with a 25-kg body weight loss over the previous three months. He had no history of herb medication or travel.

His initial blood pressure was 120/80 mmHg, pulse rate 78/min, respiratory rate 20/min, and body temperature was 36.4°C. The physical examination showed icteric sclerae and no palpable mass, abdominal distention, and shifting dullness. Laboratory findings showed white blood cell 4,190/ μ L, hemoglobin 10.2 g/dL, hematocrit 28.3%, platelet 145,000/ μ L, prothrombin time (PT) 115% of normal PT, INR 0.93, aPTT (control/test) 29.5/31.8 sec, fasting blood glucose 96 mg/dL, urea nitrogen 20.4 mg/dL, creatinine 1.41 mg/dL, total protein 6.59 g/dL, albumin 3.02 g/dL, aspartate aminotransferase (AST) 57 U/L, alanine aminotransferase (ALT) 39 U/L, alkaline phosphatase 687 IU/L, gamma-glutamyl transpeptidase (GGTP) 39 U/L, total bilirubin 56.66 mg/dL, direct bilirubin 34.84 mg/dL, alpha-fetoprotein (AFP) 613 ng/dL, and PIVKA II > 2,000 mAU/mL. The serum hepatitis B surface antigen was positive, and hepatitis C antibody was negative. Hepatitis B e antigen was negative, e antibody was positive, and HBV DNA titer was 2.0×10^3 copies/mL.

The abdominal CT scan revealed a 5.6 \times 5-cm-sized arterial enhancing, delayed-washout mass with a central necrotic portion in the caudate lobe of liver (S1), left intrahepatic bile duct dilatation, right portal vein invasion, and underlying liver cirrhosis with splenomegaly and ascites. The diagnosis was likely HCC and less likely cholangiocarcinoma (Fig. 1).

First, percutaneous transhepatic cholangiographic drainage was performed to lower the elevated bilirubin and to diminish the pruritus. The fistulography revealed hilar and proximal common hepatic duct obstruction with left intrahepatic duct dilatation (Fig. 2); this suggested

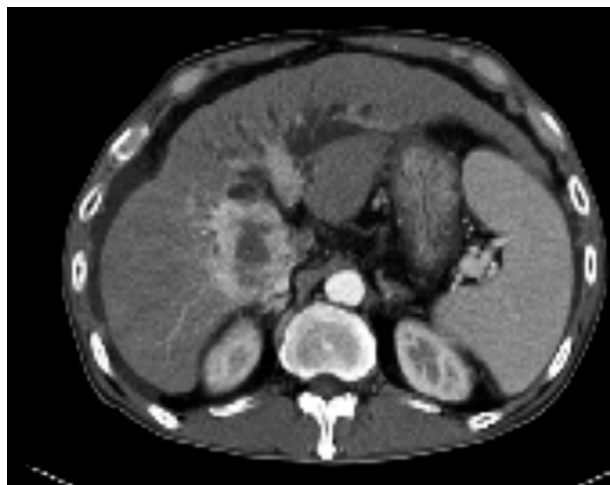

Figure 1. Abdominal computed tomography scan showing a 5.6 \times 5-cm-sized arterial and portal enhancing, delayed-washout mass with a central necrotic portion in segment 1. It is likely that intrahepatic bile duct dilatation and right portal vein and hilar invasion are also present. Underlying liver cirrhosis with splenomegaly and ascites is also present.

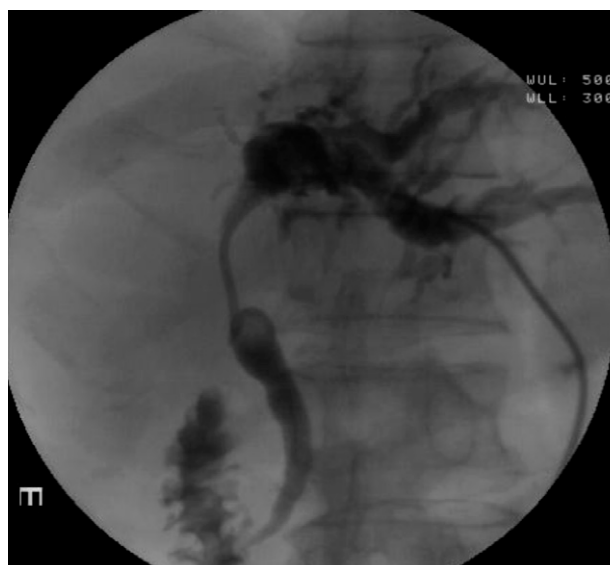

Figure 2. Percutaneous transhepatic biliary drainage showing hilar and proximal common hepatic duct obstruction with left intrahepatic duct dilatation. There is non-opacification of the right intrahepatic duct, suggesting right lobar hepatic malignancy with hilar invasion.

right lobar hepatic malignancy with hilar invasion. The level of total bilirubin was decreased from 57.66 mg/dL to 38.51 mg/dL after the procedure of external bile drainage. However, the bilirubin level was not decreased any more even though maintaining the draining catheter.

Four gold markers were inserted around the region of the target under sono guidance to act as radiographic landmarks. The CyberKnife® (Accuracy Inc., Sunnyvale,

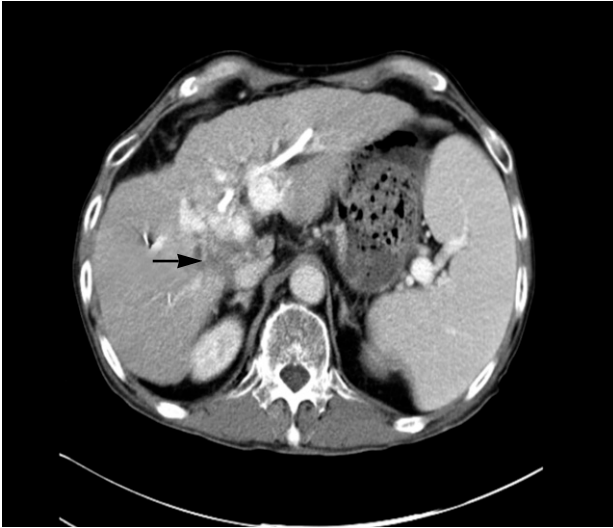

Figure 3. Abdominal computed tomography scan showing a slight decrease in the dimensions of the hypervascular mass involving the caudate lobe (4.8 × 3.2 cm).

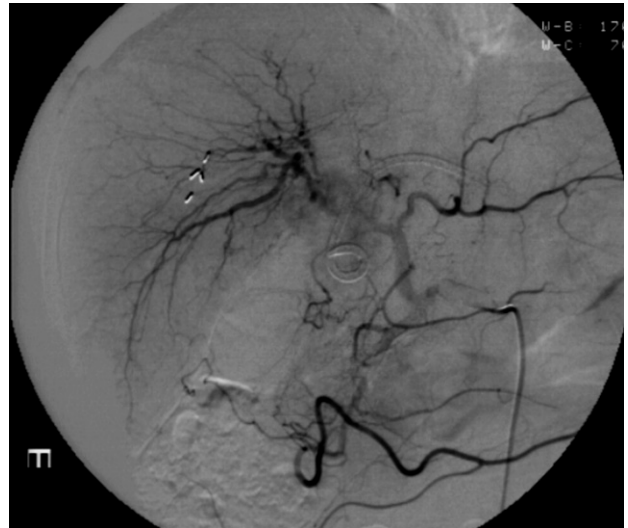

Figure 5. Angiography showing no definite hypervascular staining at the caudate lobe.

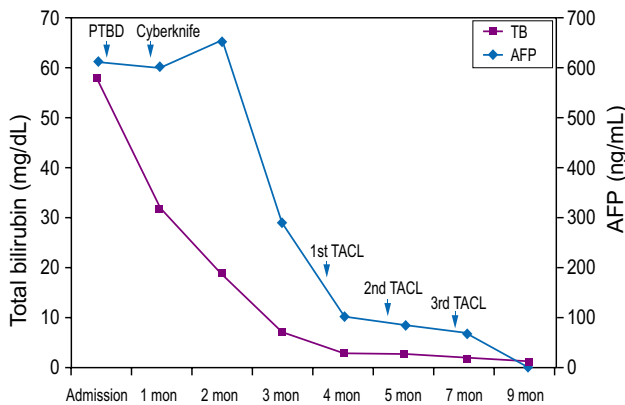


Figure 4. Changes in total bilirubin and AFP levels during the treatment. PTBD, percutaneous transhepatic cholangiographic drainage; TB, total bilirubin; AFP, alpha-fetoprotein; TACL, transarterial chemolipiodolization.

CA, USA) was targeted to the unresectable primary HCC. Circumscribed tumors were irradiated using a hypofractionated treatment. The total doses administered were 37 Gy with a prescription isodose at 80% in three fractions over three consecutive days. At 3 months after CyberKnife treatment, the size of the mass had decreased from 5.6 × 5 cm to 4.8 × 3.2 cm as determined by CT scan (Fig. 3), and total bilirubin and AFP levels had decreased from 33.60 to 9 mg/dL and 613 to 300 ng/dL, respectively. After 4 months, TACL was performed three times per month to reduce the HCC mass, and angiography showed an infiltrating HCC at the caudate lobe without definite hypervascular staining. Following consecutive post-CyberKnife TACL treatments, symptoms (jaundice, pruritus, and

abdominal discomfort) were much improved. Finally, total bilirubin and AFP levels decreased dramatically from 33.60 to 1.83 mg/dL and from 613 to 0.64 ng/dL, respectively (Fig. 4). In addition, angiography showed no tumor staining at the caudate lobe in the 3rd TACL (Fig. 5). Thereafter, liver transplantation was performed successfully two months later. The patient was followed-up regularly on an outpatient basis.

DISCUSSION

HCC is the fifth most common cancer and the third most frequent cause of death from cancer worldwide. However, in Korea, it is the third most frequent cause of death and is more prevalent among men in their fourth to fifth decades of life [5].

Jaundice occurs in 19 to 40% of patients with HCC at the time of diagnosis and usually occurs in the later stages of the disease. HCC may involve the biliary tract in several different ways: tumor thrombi, hemobilia, tumor compression, and diffuse tumor infiltration. Rarely, jaundice may be occurred due to external compression of the major bile ducts by direct tumor encasement or by metastatic lymphadenopathy at the porta hepatis. The clinical features of this type of HCC include high serum AFP level, a history of cholangitis with dilation of the intrahepatic bile duct, aggravating jaundice, and rapidly development of liver dysfunction. The total serum bilirubin level can

increase rapidly and is correlated with alkaline phosphatase and gamma-GTP levels.

Based on the underlying pathophysiology, the development of jaundice in HCC can be classified into two types: hepatocellular and cholestatic. Hepatocellular HCC is attributed to an underlying liver cirrhosis and extensive hepatic parenchymal infiltration by the tumor, which leads to hepatic parenchymal insufficiency. Over 90% of HCC cases with jaundice belong to this type. Some cases may have a reversible cause, such as reactivation of an underlying viral hepatitis or other toxic hepatitis, and should be excluded [6]. In cholestatic HCC, jaundice is caused by obstruction of the bile ducts by the tumor. Mallory et al. [7] described the first case of HCC invading the gall bladder and obstructing the extrahepatic bile ducts. The incidence of cholestatic-type HCC varies from 0.5 to 13%. Increasing recognition of cholestatic-type HCC renders classification according to therapeutic implications necessary. Lau et al. [6] classified cholestatic-type HCC into extrahepatic and the intrahepatic subtypes. This has significant therapeutic and prognostic value because those patients with EHBO secondary to HCC have a higher curative resection rate, which results in a significantly improved survival rate compared with those with intrahepatic biliary obstruction. Evidence from previous studies suggested that the management and prognosis of patients with HCC associated with jaundice depends on the underlying cause of the jaundice [8].

The management of cholestatic-type HCC includes two considerations. The first is to stabilize the jaundice by insertion of a draining catheter into the obstructed biliary tree, and the second is to assess the resectability of the tumor using appropriate investigations. Depending on the degree of biliary obstruction and the general condition of the patient, these two aspects of management can be carried out in one or two phases [8].

For patients with unresectable cholestatic-type HCC, palliative biliary drainage should be carried out. This can relieve jaundice and improve the patient's quality of life. For patients whose liver function improves after biliary drainage, other palliative treatments, such as transcatheter arterial chemoembolization, internal radiotherapy, or systemic chemotherapy, should be considered [9].

Currently, radiation therapy is the most common treatment for HCC, and it has been reported to have beneficial effects, not only on the main tumor but also on PVTT associated with HCC. However, its role is currently limited

because of the very low radiation tolerance of normal hepatic tissue [10]. The combination of three-dimensional conformal radiation therapy with TACL for HCC in cirrhotic patients was introduced as an alternative local modality, and the response rate was reported to be about 50% in HCC with PVTT [11,12]. Some authors have reported that the liver-tolerable dose depends on the volume of liver irradiated, and a small volume of liver tissue can tolerate a higher dose of radiotherapy [13]. It is not possible with conventional radiation therapy to deliver a high radiation dose to a treatment volume without exposing some normal hepatic tissue to high-dose irradiation. However, SBRT with the CyberKnife can deliver a high dose to well-defined hepatic tumors with an associated rapid dose fall-off outside the tumor volume and preservation of normal hepatic tissue. Blomgren et al. [14] were the first to report use of stereotactic radiation in the treatment of liver malignancies. They suggested a fractionated radiation schedule and reported (after exclusion of the first five patients) only one failure out of 41 liver malignancies. Herfarth et al. [2] reported that 54 (98%) of 55 tumors were locally controlled after six weeks (the initial follow-up) based on computer tomographic findings after a stereotactic single-dose radiation treatment of 60 liver tumors in 37 subjects. Recently, Kwon et al. [3] demonstrated that SBRT for small HCC less than 32 cc in tumor volume that are ineligible for local treatments showed 25 (59.6%) of 42 patients with complete response and 11 (26.2%) patients with partial response for in-field lesion. Therefore, SBRT may be preferable to either conventional or conformal radiotherapy. Furthermore, in cases of advanced or huge HCC developing obstructive jaundice, combined local SBRT with TACL therapy may prevent the tumor from spreading and lead to relief of obstructive jaundice.

The prognosis of patients with cholestatic-type HCC is generally dismal, but is usually better than that of HCC patients who have jaundice caused by hepatic insufficiency. The prognosis of this type is closely related to the stage of disease and the location and extent of tumor thrombi in the bile duct. In a study of 49 HCC patients with obstructive jaundice, Lau et al. [9] reported that nine patients received curative resection, 35 had biliary stents, and five required only supportive treatment. The overall survival rate of these patients was similar to that of HCC patients without jaundice. They concluded that good palliation and occasional cure were possible with proper treatment.

In conclusion, even though the available clinical data are insufficient to explain the outcome of this case, we believe that SBRT with TACL may represent an appropriate treatment modality for advanced HCC with obstructive jaundice due to its precision and relative safety.

Conflict of interest

No potential conflict of interest relevant to this article was reported.

REFERENCES

1. Park HC, Seong J, Han KH, Chon CY, Moon YM, Suh CO. Dose-response relationship in local radiotherapy for hepatocellular carcinoma. *Int J Radiat Oncol Biol Phys* 2002;54:150-155.
2. Herfarth KK, Debus J, Lohr F, et al. Stereotactic single-dose radiation therapy of liver tumors: results of a phase I/II trial. *J Clin Oncol* 2001;19:164-170.
3. Kwon JH, Bae SH, Kim JY, et al. Long-term effect of stereotactic body radiation therapy for primary hepatocellular carcinoma ineligible for local ablation therapy or surgical resection. Stereotactic radiotherapy for liver cancer. *BMC Cancer* 2010;10:475-484.
4. Seong J, Keum KC, Han KH, et al. Combined transcatheter arterial chemoembolization and local radiotherapy of unresectable hepatocellular carcinoma. *Int J Radiat Oncol Biol Phys* 1999;43:393-397.
5. Han KH, Kim JK. Liver cancer in Korea. *Hepatol Res* 2007;37 Suppl 2:S106-S109.
6. Lau WY, Leung KL, Leung TW, et al. Obstructive jaundice secondary to hepatocellular carcinoma. *Surg Oncol* 1995;4:303-308.
7. Mallory TB, Castleman B, Parris EE. Case records of the Massachusetts General Hospital Case. *N Engl J Med* 1947;237:673-678.
8. Lai EC, Lau WY. Hepatocellular carcinoma presenting with obstructive jaundice. *ANZ J Surg* 2006;76:631-636.
9. Lau W, Leung K, Leung TW, et al. A logical approach to hepatocellular carcinoma presenting with jaundice. *Ann Surg* 1997;225:281-285.
10. Yamada K, Izaki K, Sugimoto K, et al. Prospective trial of combined transcatheter arterial chemoembolization and three-dimensional conformal radiotherapy for portal vein tumor thrombus in patients with unresectable hepatocellular carcinoma. *Int J Radiat Oncol Biol Phys* 2003;57:113-119.
11. Seong J, Park HC, Han KH, et al. Clinical results of 3-dimensional conformal radiotherapy combined with transarterial chemoembolization for hepatocellular carcinoma in the cirrhotic patients. *Hepatol Res* 2003;27:30-35.
12. You CR, Jang JW, Kang SH, et al. Efficacy of transarterial chemolipiodolization with or without 3-dimensional conformal radiotherapy for huge HCC with portal vein tumor thrombosis. *Korean J Hepatol* 2007;13:378-386.
13. Lawrence TS, Ten Haken RK, Kessler ML, et al. The use of 3-D dose volume analysis to predict radiation hepatitis. *Int J Radiat Oncol Biol Phys* 1992;23:781-788.
14. Blomgren H, Lax I, Goranson H, et al. Radiosurgery for tumors in the body: clinical experience using a new method. *J Radiosurgery* 1998;1:63-74.