

The significance of ophthalmologic examination in a patient with xanthoma

In Sun Goak¹, Seol A Jang², Yu Jin Jin¹, In-Cheon You³, and Ji Hyun Park^{1,4,5}

¹Division of Endocrinology and Metabolism, Department of Internal Medicine, Jeonbuk National University Hospital, Jeonju; ²Division of Endocrinology, Department of Internal Medicine, Yongin Severance Hospital, Yongin; ³Department of Ophthalmology, Jeonbuk National University Medical School, Jeonju; ⁴Division of Endocrinology and Metabolism, Department of Internal Medicine, Jeonbuk National University Medical School, Jeonju; ⁵Research Institute of Clinical Medicine of Jeonbuk National University-Biomedical Research Institute of Jeonbuk National University Hospital, Jeonju, Korea

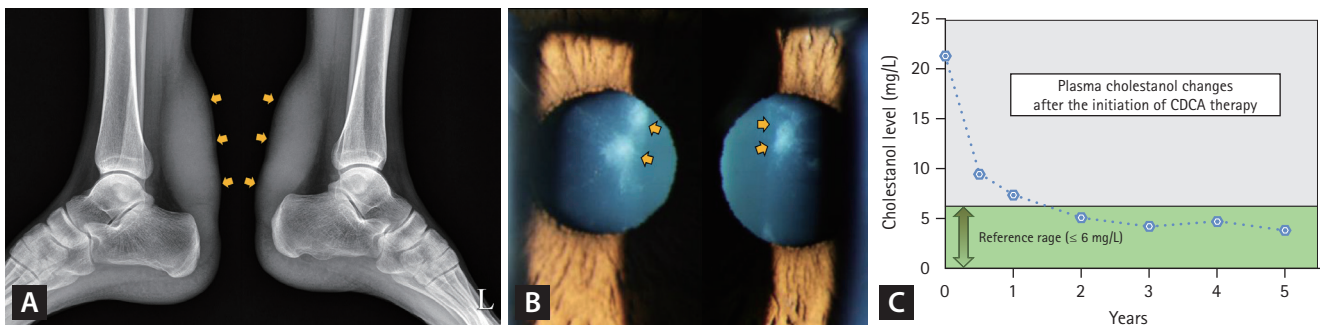


Figure 1. (A) Plain radiography shows bilateral Achilles tendon xanthomas (yellow arrows). (B) Slit-lamp examination reveals premature bilateral anterior cataracts (yellow arrows). (C) The graph illustrates changes in cholesterol levels over 5 years following the initiation of CDCA therapy. CDCA, chenodeoxycholic acid.

A 24-year-old man presented for lipid disorder evaluation before a repeat surgery for recurrent bilateral Achilles tendon xanthomas, which caused pain during walking (Fig. 1A). The patient underwent surgery for the same condition 3 years earlier. His lipid profile was total cholesterol, 195 mg/dL; low-density lipoprotein cholesterol, 130 mg/dL; triglyceride, 158 mg/dL; and high-density lipoprotein cholesterol, 59 mg/dL. Cataracts were detected during a consultation for corneal refractive surgery a year earlier. This history prompted a referral to the ophthalmology department, where a slit-lamp examination revealed premature bilateral anterior (Fig. 1B) and posterior subcapsular cataracts, raising suspicions of cerebrotendinous xanthomatosis (CTX). CTX was confirmed by an elevated plasma cholesterol level (21.33 mg/L, reference value ≤ 6.0 mg/L) and a homozygous missense mutation in the mitochondrial sterol 27-hydroxylase (*CYP27A1*) gene. Chenodeoxycholic acid (CDCA) therapy at 250 mg thrice daily, along with the use of an HMG-CoA reductase

inhibitor, resulted in a gradual reduction of cholesterol levels to normal levels over 2 years (Fig. 1C). No xanthoma recurrence, cataract progression, or other CTX-related neurologic manifestations were observed in the following 6 years. CTX results from *CYP27A1* gene mutations, reducing CDCA production and increasing plasma cholesterol levels. Untreated CTX can significantly shorten life expectancy, limiting it to the 5th and 6th decades, with progressive neurological issues such as dementia and spinal cord paresis. The absence of cholesterol in routine lipid profile may hinder accurate CTX diagnosis even when xanthomas are present. Bilateral cataracts, which occur in over 80% of patients with CTX in their 20s, provide a crucial diagnostic clue, aiding the selection of the right medication and improving patient care. Additional evaluations are necessary when a routine lipid profile does not explain why clinical signs of a lipid disorder (e.g., xanthoma) are present. Early CTX diagnosis through an ophthalmologic examination enables effective

CDCA treatment and prevents irreversible damage.

Received : August 21, 2023
Revised : September 1, 2023
Accepted : September 8, 2023

Correspondence to

Ji Hyun Park, M.D., Ph.D.
Division of Endocrinology and Metabolism, Department of Internal
Medicine, Jeonbuk National University Medical School, 20 Geonji-ro,
Deokjin-gu, Jeonju 54907, Korea
Tel: +82-63-250-1780, Fax: +82-63-254-1609

E-mail: parkjh@jbnu.ac.kr
<https://orcid.org/0000-0002-9430-8887>

Credit authorship contributions

In Sun Goak: resources, writing - original draft; Seol A Jang: resources, writing - original draft; Yu Jin Jin: resources; In-Cheon You: resources, writing - review & editing; Ji Hyun Park: conceptualization, resources, writing - review & editing, supervision

Conflicts of interest

The authors disclose no conflicts.

Funding

None