

## Secondary Renal Amyloidosis in Adult Onset Still's Disease: Case report and Review of the Literature

Young Bae Oh<sup>\*</sup>, MD., Ph.D., Sang-Cheol Bae, MD., Ph.D., MPH.  
Ja-Hun Jung, MD., Tae-Hwan Kim, MD., Ph.D., Jae-Bum Jun, MD., Ph.D.  
Sung-Soo Jung, MD., Ph.D., In-Hong Lee, MD., Ph.D., Dae-Hyun Yoo, MD., Ph.D.  
Moon Hyang Park<sup>\*\*</sup>, MD., Ph.D. and Seong Yoon Kim, MD., Ph.D.

*Department of Rheumatology<sup>\*</sup>, Tong-Inchon Ghil Hospital,  
Gachon Medical School, Incheon, 400-170, Korea  
The Hospital for Rheumatic Diseases, Department of Internal Medicine, Department of  
Pathology<sup>\*\*</sup>, Hanyang University Medical Center, Seoul, 133-792, Korea*

*We report a 25-year-old Korean woman with Adult onset Still's disease (AOSD) presented with renal amyloidosis, which had developed four years after disease onset. We successfully treated her with prednisolone, colchicine and cyclophosphamide. A review of the literature uncovered about 10 cases, most of which were treated by various regimens that resulted in poor outcomes. Renal amyloidosis should be suspected in patients with AOSD who have unexplained proteinuria. Although the mechanism of renal amyloid deposition is not well known, earlier histopathologic diagnosis and choice of regimen may affect prognosis.*

**Key Words :** *Adult onset Still's disease ; Amyloidosis*

### INTRODUCTION

Adult onset Still's disease (AOSD) is a chronic systemic inflammatory disorder in which high spiking fever, typical skin rash, and polyarthritis occur. The main biological features are neutrophilic leukocytosis, hyperferritinemia, and negative rheumatoid factor (RF) or antinuclear antibodies (ANA). Others may include splenomegaly, pleuritis, pericarditis, and hepatic abnormalities<sup>1)</sup>. Even though functional prognosis essentially depends on articular involvement, life-threatening prognosis depends on serious complications, such as hepatic failure, disseminated intravascular coagulopathy, hemophagocytosis, infections, amyloidosis, and cardiomyopathy<sup>2,5)</sup>. In this article, we describe a patient with AOSD who had secondary renal amyloidosis. We suggest a successful combined therapy of prednisolone (PD), colchicine (COL), and cyclophosphamide (CTX) and review the literature.

### CASE

A 25-year-old Korean woman was diagnosed with AOSD four years ago after experiencing a high spiking fever, maculopapular rash, and polyarthritis in her hands, elbows and knees. In laboratory findings, the leukocyte count was 19,900/μL, the serum ferritin level was 719.3 ng/mL (10-240), and RF and ANA were negative. During a follow-up, typical skin rash had disappeared after administration of PD, sulfasalazine or hydroxychloroquine and methotrexate (MTX), but either high fever or polyarthritis was wax and wane, and occasionally, intra-articular injections of corticosteroid were administered. In July 1998, she was admitted to our hospital because of slowly increasing proteinuria over a 7 month period without pitting edema or hypertension. She was single and had no family history of any rheumatic disease or drug history, such as gold or D-penicillamine.

The results of laboratory data showed that the white-cell count (WBC) was 12,800 / μL, hemoglobin (Hb) was 10.6 g/dL, platelet was 610,000 / μL, ESR was 61 mm/hr, and C-reactive protein (CRP) was 9.50 mg/dL (<0.8). The serum protein and albumin had decreased to 4.5 g/dL

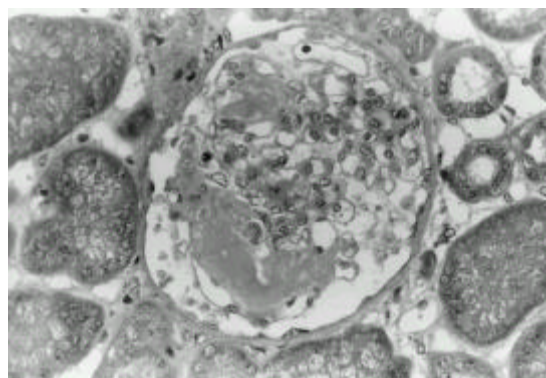
---

*Address reprint requests to : Sang-Cheol Bae, M.D.,  
Ph.D., MPH, The Hospital for Rheumatic Diseases,  
Department of Internal Medicine, Hanyang University  
Medical Center, Seoul 133-792, Korea*

(6.4-8.5) and 2.1 g/dL (3.2-5.5), respectively. Serum ferritin was within the normal range. Serum autoantibodies and rheumatoid factor were persistently negative. There was no evidence of infection or malignancy. Several urine examinations showed proteinuria without any abnormality in urinary sediments. Twenty-four hour urine protein excretion was 6.9 g/day, and urine creatine clearance was 93.3 mL/min. In radiographic findings, chest PA was normal and bony erosions were detected in both wrist joints. In the sonography, the sizes of both kidneys were 11.5cm on the right and 11cm on the left side with increased renal parenchymal echogenicity.

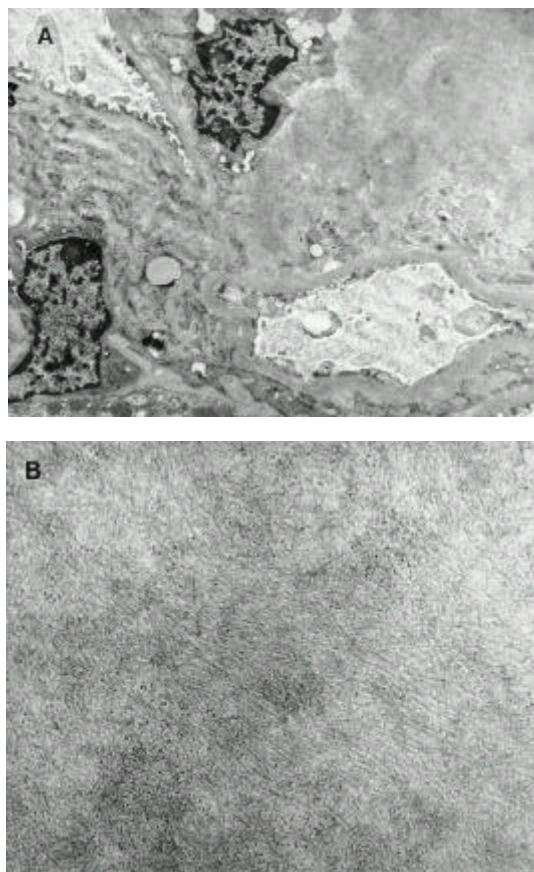
Renal biopsy showed amorphous deposits in the mesangial areas, some glomerular capillary walls and in the vascular poles (Figure 1). The amyloid deposit stained with Congo red displayed apple-green birefringence under the polarizing light. Immunofluorescence study for IgG, IgM, IgA, C3, C1, C4, fibrinogen, albumin, and light chains showed segmental positive staining for IgM and C3 in the mesangium and trace ( $\pm$ ) positive staining for light chain. Electron microscopic examination confirmed amyloid deposits in the mesangial areas, which were characterized by non-branching fibrils arranged in a random array (Figure 2A, 2B). Serum protein electrophoresis showed a decrease in both total protein and total albumin without a monoclonal spike. Urine protein electrophoresis showed an elevated total protein level and an elevated total albumin level. Therefore, the final diagnosis was made of secondary renal amyloidosis due to AOSD.

After one intravenous dosage of 500 mg methylprednisolone pulse therapy was administered. We maintained a high oral daily dose of PD (45 mg/day, 1 mg/kg), CTX (100 mg/day), and COL (1.2 mg/day). Two months later,



**Figure 1.** Amorphous deposits are located to the mesangial areas and in the vascular pole. (Masson's trichrome,  $\times 400$ ).

the PD was tapered as proteinuria decreased. After a follow-up 15 months later, laboratory tests showed that the WBC was 6,000 /uL, Hb 13.2 g/dL, platelet 297,000 /  $\mu$ L, ESR 11 mm/hr, CRP 0.11 mg/dL, and the serum protein and albumin had increased to 6.2 g/dL and 4.2 g/dL, respectively. The serum ferritin was 24.3 ng/mL. The urine protein clearance was decreased from 6.9 g/day to 92 mg/day. Currently, she is taking PD 7.5 mg, CTX 50 mg, and COL 1.2 mg orally.



**Figure 2.** Electron microscopy showed expanded mesangial matrix by amyloid deposits (A), which are characterized by non-branching fibrils arranged in random array (B). (A: $\times 4,000$ , B: $\times 35,000$ ).

## DISCUSSION

AOSD is a disorder of unknown etiology and pathogenesis. The association of amyloid deposits and AOSD is rather unusual and should be considered a serious complication. The development of amyloidosis often

SECONDARY RENAL AMYLOIDOSIS IN ADULT ONSET STILL'S DISEASE :  
CASE REPORT AND REVIEW OF THE LITERATURE

**Table 1. Comparison of renal amyloidosis diagnosed by renal biopsy in patients with adult onset Still's disease: published cases.**

Author (ref)	Age of disease onset, sex	Number of years before renal amyloidosis onset	Drug therapy for renal amyloidosis	Follow up duration after renal amyloidosis (months)	Outcome and complications
Fautrel <sup>3</sup>	32 M	ND	PD, MIX	ND	Death, Bone marrow aplasia
River <sup>7</sup>	26 M	16	PD, AZA	ND	Partial response
Hashimoto <sup>8</sup>	25 F	ND	PD	24	ND
	26 M	ND	PD	24	ND
Ishii <sup>9</sup>	32 F	7	PD, CTX	16	Death, Heart failure
Bambery <sup>4</sup>	36 F	8	Steroid, dialysis	ND	Death, Renal failure
Wendling <sup>10</sup>	57 F	4	ND	6	Gastrointestinal amyloidosis
Vigneron <sup>11</sup>	23 F	1.5	PD, hemodialysis	6	Death, Gastrointestinal amyloidosis & Renal failure
	27 F	4	PD, hemodialysis	7	Death, Renal failure
Harrington <sup>12</sup>	26 F	30	PD, COL	5	Persistent proteinuria

Note; ND: non-described, PD: Prednisolone, MIX: methotrexate, AZA: Azathioprine, CTX: Cyclophosphamide, COL: colchicine.

occurs in patients with longstanding persistent inflammatory diseases<sup>5,6</sup>. According to previous histopathologic reports on AOSD, complicated renal amyloidosis usually develops after 18 months to 30 years. The incidence of renal amyloidosis in AOSD reveals 4.7% to 14.3%<sup>3,4,7-12</sup>. We have experienced 45 patients with AOSD in our hospital and so far, found one case (2.2%) associated with renal amyloidosis<sup>13</sup>, which had developed four years after the onset of AOSD.

When this complication occurs, amyloid material is preferentially deposited in the glomeruli, and proteinuria and nephrotic syndrome are the most common initial manifestations. There was no study regarding renal pathology in patients with AOSD. Helin et al.<sup>6</sup> demonstrated in a retrospective study of nephropathy in rheumatoid arthritis (RA) that the most common histopathologic finding was mesangial glomerulonephritis (GN), followed by amyloidosis. Amyloidosis was the most common finding in nephrotic syndrome. In a patient with isolated proteinuria, amyloidosis, membranous GN, and mesangial GN were almost equally common. Membranous GN was closely related to gold or D-penicillamine therapies, whereas mesangial GN probably was related to RA itself. Biopsy is thus a valuable tool in differential diagnosis, assessment of prognosis, and decision-making with regard to treatment.

Although either NSAID or an oral steroid is usually effective in AOSD, some patients with complications of the renal amyloidosis may require sustained therapy with corticosteroid and a cytotoxic agent<sup>3,5</sup>. The COL was also

effective in a patient with severe ankylosing spondylitis and nephrotic syndrome due to amyloidosis<sup>14</sup>. In review of 10 cases with AOSD complicated by renal amyloidosis, combined drug therapy with PD, COL, CTX, azathioprine, and MIX were used<sup>3,4,7-12</sup>. In two of those cases, they were treated with steroids and dialysis due to renal failure<sup>4,11</sup>. In our experience, it has persistently decreased proteinuria as well as recovered polyarthrits or fever, without any severe complications, during the combined therapy of PD, COL, and CTX (Table 1).

In conclusion, renal amyloidosis must be suspected in patients with AOSD who have unexplained proteinuria. Although the mechanism of renal amyloid deposition is unknown, early diagnosis and treatment with PD, COL, CTX may produce excellent results.

## REFERENCES

1. Yamaguchi M, Ohta A, Tsunematsu T, Kasukawa R, Mizushima Y, Kashiwagi H, Kashiwazaki S, Tanimoto K, Matsumoto Y, Ota T, Akizuki M. *Preliminary criteria for classification of adult Still's disease. J Rheumatol* 19: 424-430, 1992
2. Pouchot J, Samplis JS, Beaudet F, Carette S, Decary F, Salussinsky-Sternbach M, Hill RO, Gutkowski A, Harth M, Myhal D, Senecal JL, Yeadon C, Esdaile JM. *Adult Still's disease: manifestation, disease course and outcome in 62 patients. Medicine* 70:118-136, 1991
3. Fautrel B, Borget C, Rozenberg S, Meyer O, Loet XL, Masson C, Koeper AC, Kahn MF, Bougeois P. *Corticosteroid sparing effect of lowdose methotrexate treatment in adult Still's disease. J Rheumatol* 26: 373-378, 1999

4. Bamberg P, Thomas RJ, Malhotra HS, Kaur U, Bhusnumath SR, Deodhar SD. *Adult onset Still's disease: clinical experience with 18 patients over 15 years in northern India. Ann Rheum Dis 51:529-532, 1992*
5. Gertz MA, Kyle RA. *Amyloidosis: Prognosis and Treatment. Semin Arthritis Rheum 24:124-138, 1994*
6. Helen HJ, Korpeka MM, Mustonen JT, Pasternack AI. *Renal biopsy findings and clinicopathologic correlations in Rheumatoid arthritis. Arthritis Rheum 38:242-247, 1995*
7. Rivera F, Gil MC, Gil MI, Batle-Guaska E, Triqueros M, Olivares J. *Vascular renal AA amyloidosis in adult Still's disease. Nephrol Dial Transplant 12:1714-1716, 1997*
8. Hashimoto M, Shingu M, Ezaki I, Yoshikawa Y, Nobunaga M. *Clinical studies on 4 cases of adult-onset Still's disease. Nihon Rinsho Meneki Gakkai Kaishi 18:45-52, 1995*
9. Ishii T, Sasaki T, Muryoi T, Murai C, Hatakeyama A, Oosaki H, Yusa A, Kawanami T, Yoshinaga K. *Systemic amyloidosis in a patients with adult onset Still's disease. Intern Med 32:50-52, 1993*
10. Wending D, Humbert PG, Billerey C, Fest T, Dupond JL. *Adult onset Still's disease and related renal amyloidosis, Ann Rheum Dis 50:257-259, 1991*
11. Vigneron AM, Kaplan G, Labrousse C, Leroux-Robert C, Rene E, Kahn MF. *Amyloidosis in adult Still's disease. Apropos of 2 case. Ann Med Interne(Paris) 137:406-408, 1986*
12. Harrinton TM, Moran JJ, Davis De. *Amyloidosis in adult onset Still's disease. J Rheumatol 8:833-836, 1981*
13. Cho KS, Yoo DH, Yun HR, Lee MH, Lee JK, Shim SC, Chang DK, Yoo TS, Koh HK, Kim TH, Jun JB, Jung SS, Lee IH, Bae SC, Kim SY. *Adult onset Still's disease: Clinical features and prognostic factors in Korea. J Kor Rheum Ass 5:64-75, 1998*
14. Escalante A, Ehresmann GR, Quismorio FP. *Regression of reactive systemic amyloidosis due to ankylosing spondylitis following the administration of colchicine. Arthritis Rheum 34:920-922, 1991*