

Infected Pneumatocele Following Anaerobic Pneumonia in Adult

Sang Hyun Kim, M.D., Yeon Tae Chung, M.D., Kyung Duk Lee, M.D.,
Kyoung Youn Seon, M.D., Jong Hyun Lee, M.D.,
Sung Ho Lee, M.D. and Se Ho Choi, M.D.

Department of Internal Medicine, National Medical Center, Seoul, Korea

We report a case of an infected pneumatocele in the course of anaerobic pneumonia in an adult. To the best of our knowledge, anaerobic pneumonia complicated by a pneumatocele in an adult has not previously been described. The pneumatocele occurred on the fifth day of hospitalization, and rapidly increased in size, with the development of a subsequent mixed anaerobe infection. A pig-tail catheter was inserted and the pus drained. The bacterial culture from the pus was positive for three anaerobes: Bacteroid species, Peptostreptococcus asaccharolyticus and Fusobacterium species. Intravenous antibiotics and percutaneous catheter drainage resulted in a successful treatment.

Key Words : Pneumatocele, Infected pneumatocele, Anaerobic pneumonia

INTRODUCTION

Pulmonary pneumatoceles are thin-walled, gas-filled cysts that develop within the lung parenchyma. They can be single emphysematous lesion, but are more often multiple. Most often, they occur as a complication of acute pneumonia, commonly caused by *Staphylococcus aureus*^{1, 2)}. However, pneumatoceles are also caused by other agents, including *Streptococcus pneumoniae*³⁾, *Haemophilus influenzae*⁵⁾, *Pseudomonas aeruginosa*⁵⁾, *Escherichia coli*⁶⁾, *Klebsiella pneumoniae*^{5, 6)}, *Mycobacterium tuberculosis*⁷⁾, *Proteus mirabilis*⁸⁾, *Serratia marcescens*⁶⁾ and *Pneumocystis jiroveci*⁹⁾ and also by trauma¹⁰⁾ and hydrocarbon-induced pneumonia¹¹⁾.

Pneumatocele is commonly seen in infants and young children as a complication of staphylococcal pneumonia^{1, 2)}. However, pneumatoceles are unusual found in adults with pneumonia⁴⁾. However, anaerobic pneumonia, complicated by pneumatocele, has not previously been described.

CASE REPORT

A 64-year-old man was admitted with a history of severe right pleuritic chest pain of a few days duration. He had been treated for diabetes mellitus and hypertension for twenty years, which were well controlled, without any complications. He also had a history of pulmonary tuberculosis, but denied alcoholism and drug abuse.

On admission, he had respiratory symptoms, including a mild cough, yellowish sputum and severe right pleuritic chest pain. He also had mild fever, with a body temperature of 37.3°C, pulse rate 103/min, respiratory rate 18/min and blood pressure 150/80 mmHg. A chest examination revealed decreased breathing sound in the right lower lung. Laboratory studies revealed the following values: leukocytes 21,500/cu mm with 84% segmental neutrophil, 3% band forms, 10% lymphocyte and 4% monocytes; arterial pH 7.41, PCO₂ 37.5 mmHg, PO₂ 60.7 mmHg on room air.

The chest radiography taken on admission revealed a loculated pleural effusion, with suspicious consolidation in the right lower lung. A blood culture was obtained and treatment

·Received : March 3, 2005

·Accepted : May 16, 2005

·Correspondence to : Sang Hyun Kim, M.D., Department of Internal Medicine, National Medical Center, 18-79 Ulji-ro 6 ka Joong-Ku, Seoul 100-196, Korea Tel : 82-2-2260-7270, Fax : 82-2-2269-7036, E-mail : kim4319707@daum.net

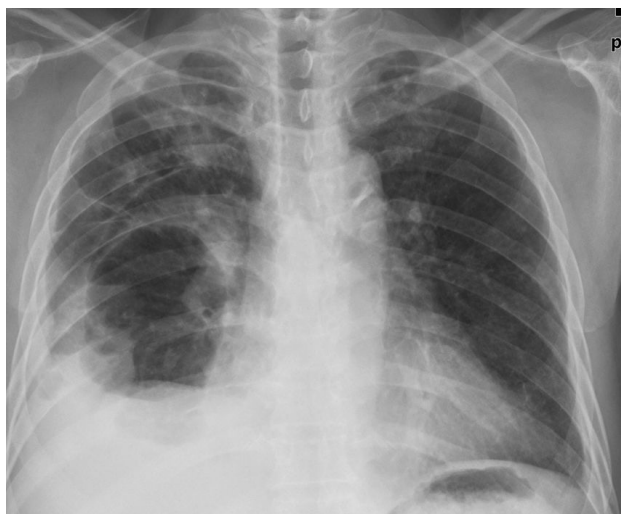

Figure 1. On the fifth day of hospitalization, chest radiography showed a newly developed air-cyst and air fluid level in the right lower lung.

was started with intravenous antibiotics (cefpiramide 1 g every 12 hours and amikacin 500 mg every 24 hours). Sono-guided thoracentesis was performed. The pleural fluid contained a pus-like material: WBC > 1,000/mm³ almost PMNL; glucose 346 mg/dL; protein 4.3 mg/dL; LDH 2211 u/L. Bacteria, fungi and tuberculosis cultures were all negative, as were the blood and sputum cultures. On the fifth day of hospitalization, chest radiography revealed an air cyst and air fluid level in the right lower lung (Figure 1). On the ninth day, the size of the air-cyst had rapidly increased to about 9×11 cm in size; the air fluid level had also increased (Figure 2A).

Computed tomography of the chest was performed, and the

enhanced chest CT scan showed a 9×11 cm-sized thin-walled cavitory lesion, with an air fluid level, pleural effusion and consolidation in the right lower lung (Figure 2B).

A percutaneous pig-tail catheter was inserted into the pneumatocele with the air fluid level, and foul-odored pus drained. The bacterial culture was positive for *Bacteroid* species, *Peptostreptococcus asaccharolyticus* and *Fusobacterium* species. On the same day, antibiotics were changed to intravenous clindamycin, 600 mg every 8 hours. On the next day, after percutaneous catheter drainage, the patient became afebrile, and the size and amount of the air fluid level of the pneumatocele progressively decreased. On the twenty-seventh day, there was no further drainage and the catheter was removed. Eventually, the patient was discharged on the thirty-sixth day of hospitalization.

DISCUSSION

A pulmonary pneumatocele can occur in association with acute pneumonia, and is almost transient as the lesions generally resolve spontaneously and completely without sequelae^{1, 2, 5}. Pneumatoceles are differentiated from lung abscesses due to their tendency to rapidly change in appearance, size and location¹.

The precise pathogenesis and pathological anatomy of pneumatoceles are in most instances uncertain¹³. Recently, Quigley and Fraser proposed a pathogenesis, which after the cavity had formed, irritation and inflammation of a small draining bronchiole led to the formation of a mucus flap, focally adherent to the airway wall. The intracavitary portion, being mobile, could

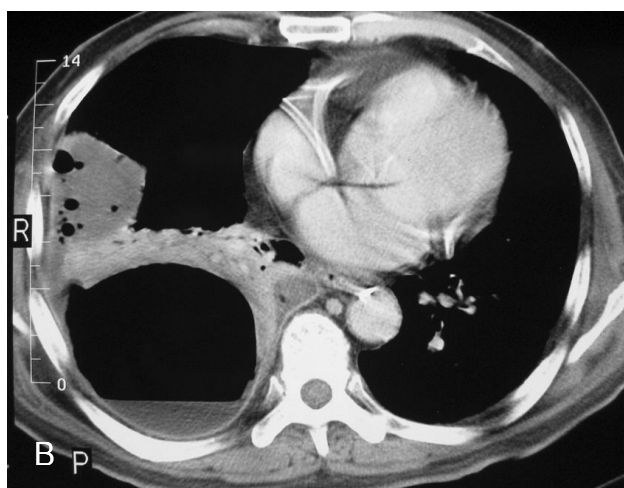
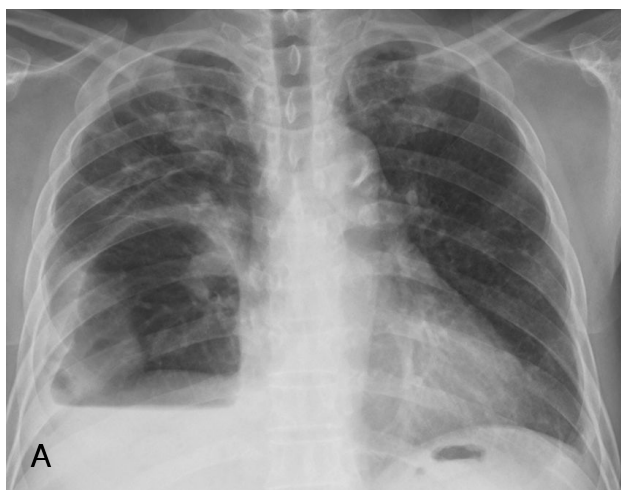

Figure 2. On the ninth day of hospitalization, (A) Chest radiography showed the increased size of the air-cyst and air fluid level in the right lower lung. (B) Enhanced chest CT scan showed a 9×11 cm sized, thin-walled cavitory lesion, with an air-fluid level, pleural effusion and consolidation in the right lower lung.

alternatively open and close the bronchiolar orifice, effectively acting as a check-valve¹³⁾.

Radiological evidence of pneumatoceles most often occurs on the fifth to sixth day of hospitalization⁵⁾, but on rare occasions may be visible on the initial chest radiograph. The usual medical care of pneumatoceles in the course of pneumonia is the treatment of the underlying pneumonia, but tension pneumatoceles, pneumothorax and infected pneumatoceles, which can be life-threatening, may require surgical intervention, such as catheter drainage and an operation¹²⁾.

In our patient, the pneumatocele formed on the fifth day of hospitalization, and the size and amount of the air fluid level gradually increased. Large pneumatoceles can cause displacement and compression of the adjacent lung, resulting in cardiopulmonary insufficiency, but our patient had no pneumatocele-related symptoms. In most circumstances, pneumatoceles are asymptomatic and do not require surgical intervention. The majority of pneumatoceles resolve spontaneously over weeks to months, and without significant clinical or radiographic sequelae^{1, 2)}.

Treatment of the underlying pneumonia with antibiotics is the first line of therapy. Percutaneous catheter drainage is helpful, both as a diagnostic and therapeutic procedure for the pneumatocele and its complications^{12, 14)}. In our case, percutaneous catheter drainage of the pneumatocele infected by the mixed anaerobes was performed. It is also helpful to diagnose and treat the pneumatocele. Despite our efforts, we could find no similar case of anaerobic pneumonia complicated by pneumatoceles.

In summary, we report a case of an adult patient with anaerobic pneumonia, complicated by a pneumatocele, with secondary infection. The infected pneumatocele was successfully decompressed and drained using percutaneous catheter drainage. Our patient was successfully treated with antibiotics and percutaneous catheter drainage.

REFERENCES

- 1) Meyers HI, Jacobson G. *Staphylococcal pneumonia in children and adults. Radiology* 72:665-671, 1959
- 2) Ceruti E, Contreras J, Neira M. *Staphylococcal pneumonia in childhood. Am J Dis Child* 122:386-392, 1971
- 3) Kevy SV, Lowe BA. *Streptococcal pneumonia and empyema in childhood. N Engl J Med* 264:738-743, 1961
- 4) McGarry T, Giosa R, Rohman M, Huang CT. *Pneumatocele formation in adult pneumonia. Chest* 92:717-720, 1987
- 5) Amitar I, Mogle P, Godfred S, Aviad I. *Pneumatocele in infants and children. Clin Pediatr* 22:420-422, 1983
- 6) Khan EA, Wafelman LS, Garcia-Prats JA, Taber LH. *Serratia marcescens pneumonia, empyema and pneumatocele in a preterm neonate. Pediatr Infect Dis J* 16:1003-1005, 1997
- 7) Madden RE, Viswanathan TK, Verghese KP. *Solitary pneumatocele in childhood tuberculosis. Ann Thorac Surg* 5:347-351, 1968
- 8) Lysy J, Werczberger A, Globus M, Chowder I. *Pneumatocele formation in a patient with proteus mirabilis pneumonia. Postgrad Med J* 61:255-257, 1985
- 9) Jacob CN, Henein S, Hill AR. *AIDS-related Pneumocystis pneumonia complicated by diffuse pneumatocele formation. N Y state J Med* 92:20-21, 1992
- 10) Schimpl G, Schneider U. *Traumatic pneumatocele in an infant. Eur J Pediatr Surg* 6:104-106, 1996
- 11) Bergeson PS, Hales SW, Lustgarten MD, Lipow HW. *Pneumatoceles following hydrocarbon ingestion. Am J Dis Child* 129:49-54, 1975
- 12) Zuhdi MK, Spear RM, Worthen HM, Peterson BM. *Percutaneous catheter drainage of tension pneumatocele, secondarily infected pneumatocele, and lung abscess in children. Crit Care Med* 24:330-333, 1996
- 13) Quigley MJ, Fraser RS. *Pulmonary pneumatocele: pathology and pathogenesis. AJR Am J Roentgenol* 150:1275-1277, 1988
- 14) DiBardino DJ, Espada R, Seu P, Goss JA. *Management of complicated pneumatocele. J Thorac Cardiovasc Surg* 126:859-861, 2003